

## HISTOPATHOLOGICAL ALTERATIONS ASSOCIATED WITH *HYMENOLEPIS DIMINUTA* (RUD., 1819) LARVAE IN THE LIVER OF *RATTUS NORVEGICUS* (BERKENHOUT, 1767)

Erum Khadijah<sup>1</sup>, Arshad Azmi<sup>1</sup>, Aly Khan<sup>2</sup> and \*Nasira Khatoon<sup>1</sup>

<sup>1</sup>Department of Zoology, University of Karachi, Karachi-75270

<sup>2</sup>Crop Diseases Research Institute, PARC, University of Karachi, Karachi-75270

\*Corresponding Author: Email: nasiraparvez.uok@gmail.com

---

### ABSTRACT

The present work was undertaken to study the histopathological changes in the liver of rat *Rattus norvegicus* (Berkenhout, 1769) infected with *Hymenolepis diminuta* (Rud. 1819) larvae. Histopathological sections of infected liver were prepared by fixing small pieces of liver in buffer formalin for 24 h. The fixed material was dehydrated and prepared for block making by the usual procedure. Eosin and Hematoxylin stained serial section were mounted permanently in DPX. Sections were examined in detail and photomicrographs of selected section were taken by Nikon (Aptiphot-2) photomicroscope using Fuji Color Film. Histopathological study of selected portions of the liver revealed that *H. diminuta* larvae severely affected the whole morphology of the liver cells. Pronounced changes included pyknosis, necrosis, hypertrophy, hyperplasia and dislocation of liver tissue. Eosinophil aggregation along with caseous necrosis was obvious.

**Key-words:** *Rattus norvegicus*, Histopathology, *Hymenolepis diminuta* (Rud., 1819), liver, Pakistan.

---

### INTRODUCTION

*Rattus norvegicus* (Berkenhout, 1769) is the most efficient burrower among the *Rattus* species. They excavate extensive tunnels under the foundation of buildings and also occupy drains and underground sewerages. It is exclusively a commensal species in Pakistan, found only in towns. *Rattus norvegicus* is a serious pest in Karachi, particularly famous for destroying rice and wheat stocks. *Rattus norvegicus* also produces a major health hazard to human. They carry a number of diseases and parasites such as helminths, bacteria, protozoa, rickettsia and viruses, as well as parasites and also serve as intermediate host for helminths. The clinical investigation and microscopic findings were consistent with metastatic hepatic sarcoma induced by *Taenia taeniaeformis* (Irrizarry-Rovira *et al* 2007).

Cestode larvae were reported to be within cystic cavities in the centre of the hepatic mass and in the remaining liver tissue (Blaies and Williams 1983). Similarly gastrointestinal hyperplasia in chronically infected rats was common (Conchedda and Ferette 1984). Rikihisa and Lin (1984) studied susceptibility of different strains of mice to various levels of infection with the eggs of *Taenia taeniaeformis*. Susceptible strains allow primary infection to develop. They show resistance to challenge infection because larvae are destroyed before they become insusceptible to host attack. *Taenia taeniaeformis* increases cell growth and neutral mucus production in the gastric mucosa of the rat with a larval infection. Cysticercoids larvae also promote white blood cell changes (Ansari and Williams 1976). In the present study histopathology of rat (*Rattus norvegicus* Berkenhout, 1769) naturally infected with *Hymenolepis diminuta* is being reported.

### MATERIALS AND METHODS

Rats (*Rattus norvegicus* Berkenhout, 1769) were trapped from Karachi during 2012. A single rat liver was found to be infected with *Hymenolepis diminuta* larvae. Pieces of infected liver with larvae were fixed in 5% buffer formalin for 24 h, then washed several times with 70% alcohol to remove as much as possible the fixative. The material was dehydrated in graded series of ethyl alcohol (70%, 90% and 100%). Small pieces of liver were then transferred to cedar wood oil for 8-12 hours. Cedar wood oil was slowly removed by placing there in a mixture of equal amounts of cedar wood oil and xylol and then into pure xylol for 2 h. Wax block of specimens was made in L-blocks by usual procedure. Sections were gently cut at a thickness of 6-8 microns and stained with Hematoxylin and eosin and mounted permanently in Canada balsam by usual procedure. For preparing photomicrographs of selected portion of infected liver Fuji 400 colour film was used on Nikon (optiphot-2) photomicroscope.

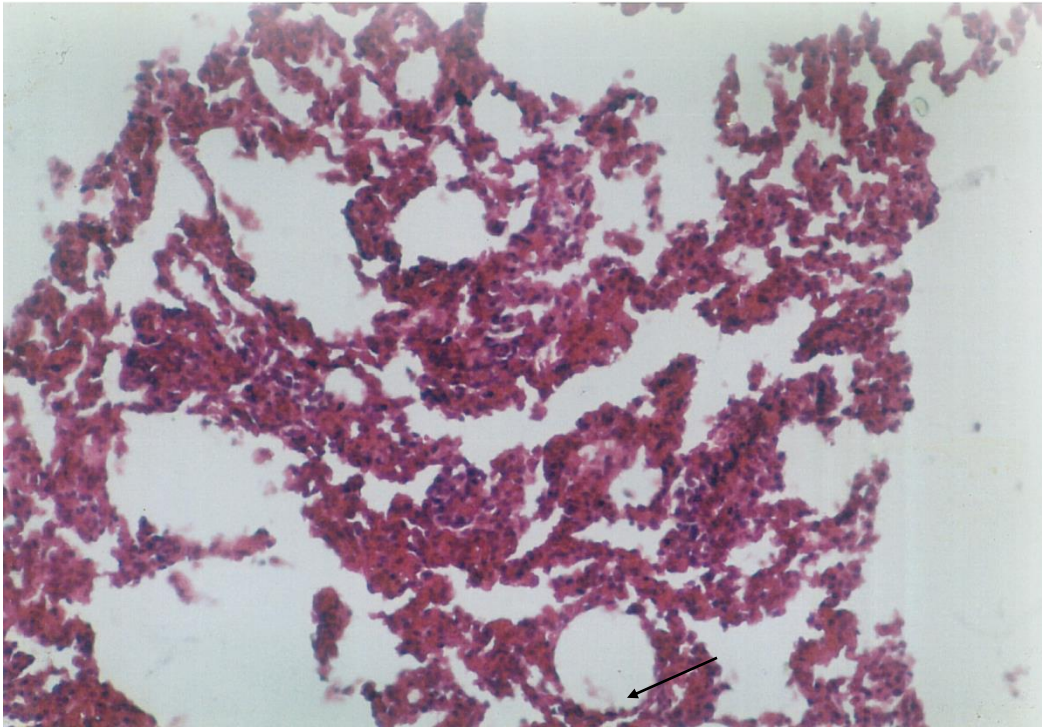


Fig. 1. Photomicrograph of a portion of liver showing total destruction of cellular architecture and morphology (x100).

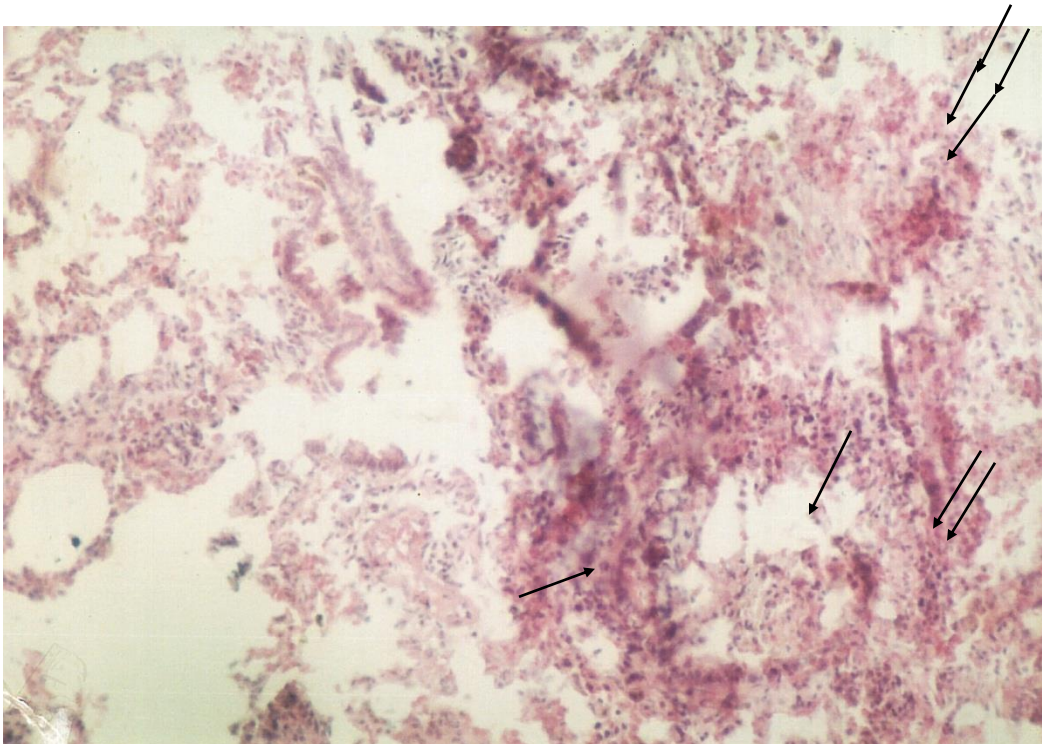


Fig. 2. Portion of liver section showing atrophy, necrosis (arrow) and pyknosis (double arrow) (x50).

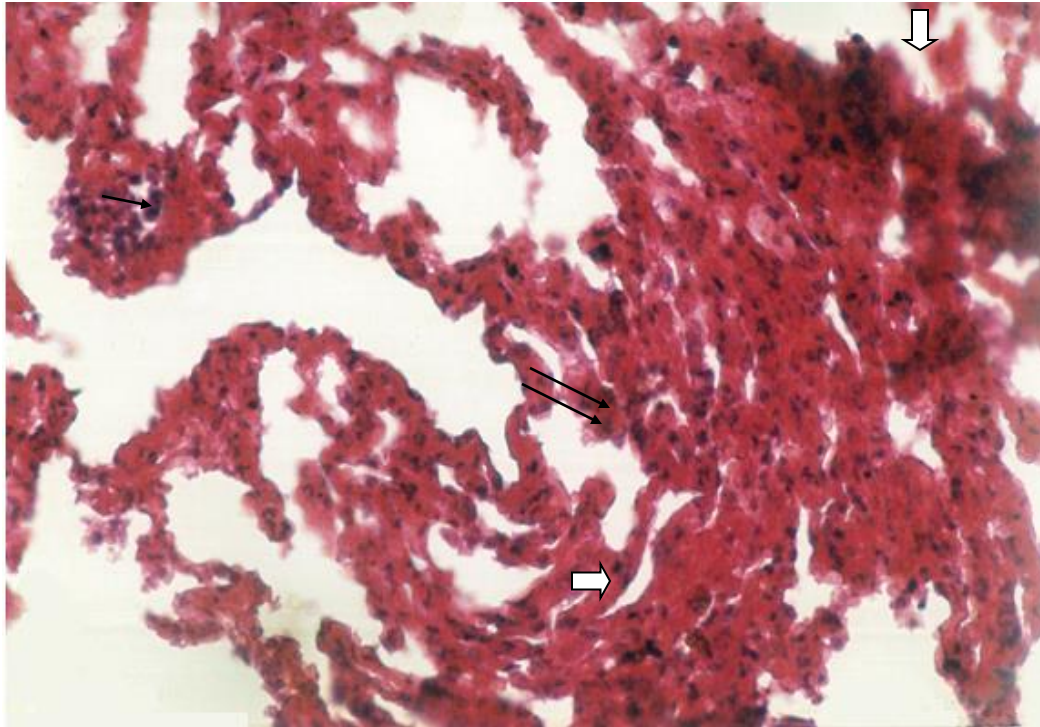


Fig. 3. Portion of liver section showing hepatocyte fusion which leads to fibrosis (double arrows). Eosinophil (arrow) aggregation apparent in the destroyed vein along with caseous necrosis (short arrow) (x200).

## RESULTS AND DISCUSSION

Histopathological study of selected portion of liver revealed that cestode, *H. diminuta* larval parasites severely affected the whole morphology of the liver. Pronounced changes included atrophy of the villi and underlying tissues as a common finding. Granulomatous tissues masses and granulation lesions were also obvious leading to complete destruction of cellular architecture and morphology (Fig. 1). Proliferation of liver was reported by White *et.al* (1982) in two strains of mice due to *Mesocostoides corti*. Hypertrophy and hyperplasia of the glandular region was recorded. In some section atrophy, necrosis along with pyknosis was a common finding (Fig. 2). Letonja *et al.* (1987) reported *Taenia taeniaeformis* early inflammatory response around developing metacestode in the liver of resistant and susceptible mice. Villi were completely lost where cysticercoids larva penetrated. Infiltration of lymphocyte and macrophages were also obvious. Necrosis was prominent, long migratory tunnels were seen due to the penetration of cysticercoids larvae. Hypertrophy and hyperplasia of the glandular region was also observed. In some sections hepatocyte fusion could be seen which eventually leads to fibrosis. Eosinophils aggregation along with caseous necrosis was observed (Fig. 3). The eosinophil aggregation observed here could be a reliable measure of eosinophil activation as observed earlier in Guinea Pig (Teixeira *et.al* 1995).

*H. diminuta* infection may lead to disease condition or even mortality in affected rats.

## REFERENCES

- Ansari, A and J. F. Williams (1976). The eosinophilic response of the rat to infection with *Taenia taeniaeformis*. The Journal of Parasitology., 62(5): 728-736.
- Berkenhout, J. (1769). Outlines of the natural history of Great Britain and Ireland containing a systematic arrangement and concise description of all the animals, vegetables and fossiles which have hitherto been discovered in these Kingdoms. Vol.1. Comprehending the animal Kingdom. pp XIII + 233 pp, London.
- Blaies, D.M. and F.J. Williams (1983). *Taenia taeniaeformis* gasterointestinal hyperplasia in chronically infected rats. Experimental Parasitology., 55(2): 197-206.
- Conchedda, M. and G. Ferruti (1984). Susceptibility of different strains of mice to various levels of infection with the eggs of *Taenia taeniaeformis*. International Journal for Parasitology., 14(6): 541-546.

- Irizary-Rovifa, A.R; A. Worf and M. Bolek (2007). *Taenia taeniaeformis* induced metastatic hepatic sarcoma in pet rat (*Rattus norvegicus*). *Journal of Exotic Pet Medicine*. 16 (1): 45-48.
- Letonja, T., C. Hammerberg and G. Shurig (1987). Evaluation of spleen lymphocyte responsiveness to a T-cell nitrogen during early infection with larval *Taenia taeniaeformis*. *Parasitol. Res.* 73: 265-270.
- Rikihsa, Y. and C.Y. Lin (1984). *Taenia taeniaeformis* increased cell growth and neutral mucus production in the gastric mucosa of the rat with a larval infection. *Experimental Parasitology.*, 58(2): 147-155.
- Teixeira, M.M; T.J. Williams, B.T. Au, P.G. Hellewell and A.G. Rossi (1995). Characterization of eosinophil homotypic aggregation. *J. Leukoc Biol.*, 57: 226-234.
- White, T.R; P.C. Thompson, W.J. Pen hale, D.A. Pass and J.N. Mills (1982). Pathophysiology of *Metacystoides corti* infection in the mouse. *J. Helminthol.*, 36: 145-143.

(Accepted for publication December 2016)